

Sylvie MEAUME¹
 Anne LE PILLOUER-PROST²
 Bertrand RICHERT³
 Diane ROSEEUW⁴
 Javid VADOUD⁵

¹ APHP, Hôpital Rothschild,
 Service de Gériatrie – Plaies et Cicatrisation,
 75012 Paris,
 France

² Dermatology Department,
 Private Hospital Clairval,
 13009 Marseille,
 France

³ Dermatology Department,
 University Hospitals Brugmann - Saint
 Pierre - Queen Fabiola Children's Hospitals
 Université Libre de Bruxelles
 1020 Brussels,
 Belgium

⁴ Dermatology Department,
 UZ Brussel, Vrije Universiteit Brussel,
 1090 Brussels,
 Belgium

⁵ Dermatology Department,
 Clinique du Parc Léopold,
 Rue Froissart 38,
 1040 Brussels,
 Belgium

Reprints: J. Vadoud
 <drvadoud@gmail.com>

Article accepted on 2/14/2014

Management of scars: updated practical guidelines and use of silicones

Hypertrophic scars and keloids resulting from surgery, burns, trauma and infection can be associated with substantial physical and psychological distress. Various non-invasive and invasive options are currently available for the prevention and treatment of these scars. Recently, an international multidisciplinary group of 24 experts on scar management (dermatologists; plastic and reconstructive surgeons; general surgeons; physical medicine, rehabilitation and burns specialists; psychosocial and behavioural researchers; epidemiologists; beauticians) convened to update a set of practical guidelines for the prevention and treatment of hypertrophic and keloid scars on the basis of the latest published clinical evidence on existing scar management options. Silicone-based products such as sheets and gels are recommended as the gold standard, first-line, non-invasive option for both the prevention and treatment of scars. Other general scar preventative measures include avoiding sun exposure, compression therapy, taping and the use of moisturisers. Invasive treatment options include intralesional injections of corticosteroids and/or 5-fluorouracil, cryotherapy, radiotherapy, laser therapy and surgical excision. All of these options may be used alone or as part of combination therapy. Of utmost importance is the regular re-evaluation of patients every four to eight weeks to evaluate whether additional treatment is warranted. The amount of scar management measures that are applied to each wound depends on the patient's risk of developing a scar and their level of concern about the scar's appearance. The practical advice presented in the current guidelines should be combined with clinical judgement when deciding on the most appropriate scar management measures for an individual patient.

Key words: Guidelines, Prevention, Scar, Silicone gel, Silicone sheet, Treatment

Scars are an undesirable, yet normal outcome of wound healing [1]. Hypertrophic scars usually remain within the border of the original wound and may spontaneously regress over time, whereas keloid scars extend further beyond the wound's margins and remain elevated [1, 2]. Scars are especially likely to occur after a deep wound which extends through the dermis into the subdermal tissue [3]. They occur with equal frequency in men and women, although injuries in adolescents and young adults generally produce worse scarring compared with those in elderly people [2, 4]. Hypertrophic scars and keloids frequently occur in areas of the body that are subject to stretching tension, such as the deltoid, sternal and supra-pubic regions and the lower abdomen. Furthermore, people with pigmented skin are more likely to develop keloids compared to those with white skin [2]. Hypertrophic scars and keloids are not only physically disfiguring and psychologically distressing, but they also can cause significant pain and itching [1, 2].

Dermatologists now have many different treatment options for the prevention and treatment of scars. These include non-invasive treatments such as silicone sheets or gels, tape, compression therapy and physiotherapy, as well as invasive

treatments such as intralesional corticosteroid injections, 5-fluorouracil injections, cryotherapy, radiotherapy and laser therapy. These treatments can be used alone or as part of combination therapies. Patients often present to dermatologists once they have a maturing or matured hypertrophic scar or keloid. In many cases, earlier consultation with a dermatologist may be more effective, since scars are often easier to prevent than to treat.

To assist physicians such as dermatologists who are involved in scar management to select the most appropriate treatment for their patients, a set of practical guidelines for the prevention and treatment of hypertrophic scars and keloids was recently developed by a multidisciplinary group of 24 experts (including dermatologists; plastic and reconstructive surgeons; general surgeons; physical medicine, rehabilitation and burns specialists; psychosocial and behavioural researchers; epidemiologists; and beauticians) from seven countries [5]. These guidelines were developed using the latest clinical evidence on scar management measures that has been reported since the publication of a previous set of scar management guidelines in 2002 [6]. The aims of the current article are to discuss the key aspects of the current guidelines that are of relevance to

dermatologists involved in scar management and to thoroughly evaluate the latest clinical evidence for the use of silicone therapy on which the recommendations in the guidelines are based.

Scar management practical guidelines

Practical guidelines for the prevention and treatment of hypertrophic scars and keloids developed by an international, multidisciplinary group of experts are shown in *figure 1*. Most scar management measures can be used for both prevention and treatment. The treating physician should always re-evaluate the patient every four to eight weeks to determine whether or not additional therapeutic options need to be considered [5].

Preventive measures

Immediate priorities for scar prevention include rapid wound closure, early debridement of dead tissue, measures to prevent or treat inflammation and infection, and provision of adequate wound dressings to establish a moist wound healing environment [5]. The amount of preventive measures that should be applied to a newly formed wound depends on the individual patient's risk factors for scar formation (e.g., type and location of wound, age and skin type) and the level of aesthetic concern the patient has about scar formation.

General preventive measures, as recommended in the latest guidelines include: sun protection, the use of moisturising creams and the use of moisture retentive dressings such as silicone gel [5]. Transepidermal water loss is increased in hypertrophic scars and keloids [7]. The subsequent dehydration of keratinocytes may stimulate the production of cytokines, leading to excessive collagen deposition by fibroblasts, which results in scar formation [8]. Moisturisers increase the water (or moisture) content of the skin, whereas silicone-based dressings help to decrease the evaporation of water through the skin and to restore the barrier function of the skin, which can help to reduce scar formation [9]. Other preventive measures include taping, splinting or stretching, and physical treatments such as manual massage, endermology and physiotherapy [5].

Treatment of hypertrophic scars and keloids

As shown in *figure 1*, first-line non-invasive treatment options for linear and widespread hypertrophic scars and keloids include silicone-based products such as sheets and gels and compression therapy [5]. Both treatments should be applied only once the wound has closed. Early treatment is essential, particularly for those with widespread hypertrophy from burns, trauma or infection. These patients should be referred to a dermatologist as soon as possible and treated with custom-made pressure garments with silicone inlays [5].

Patients with linear scars and continuing hypertrophy after six months should continue their first-line therapy and should initiate second-line therapy with intralesional corticosteroids. Triamcinolone acetonide is the most commonly used corticosteroid with the current guidelines recommending a dose of 40 mg/mL every two to four weeks when

used as monotherapy, until the scar is flattened [5]. Patients with widespread hypertrophic scars may be treated with corticosteroids at an earlier stage in the maturation of their scar. Intralesional corticosteroids may be supplemented with 5-fluorouracil in those with refractory scars. Similarly, patients with growing keloids may be treated with intralesional corticosteroids with or without other agents such as 5-fluorouracil, bleomycin or verapamil, in addition to first-line treatment with silicones and compression therapy.

Surgical scar revision or resurfacing may be offered to patients with hypertrophic scars after 12 months of treatment. Surgery must also be considered earlier for those with functional impairment, e.g., by contracture release. Keloids that have not responded to 12 months of treatment may be surgically excised, but this should be combined with radiotherapy or intralesional cryotherapy to reduce the high rate of recurrence of these scars [2, 5].

The specific treatment options recommended in these guidelines are discussed in more detail in the following sections.

Non-invasive management options

The two principal non-invasive management options recommended in the guidelines for scar prevention and treatment are silicone products and compression therapy. Medical ointments and creams may be useful for reducing scar pruritus and physical therapies may also be valuable as part of overall scar management.

Silicone sheets and gels

Silicone-based products for scar management have been available for the past 30 years and are recommended in the current guidelines as the "gold standard" option for the prevention and treatment of hypertrophic scars and keloids [5, 10]. Silicones have been manufactured in various forms such as silicone sheets and more recently silicone gels [11].

Silicone sheets have to be worn over the scar for 12–24 hours each day for three to six months [5]. The sheets can be used until they begin to disintegrate but need to be washed daily with mild soap and water to prevent side effects such as rashes and infections. The composition of different silicone sheets varies widely, with some only containing medical grade silicone whereas others contain a combination of silicone and polytetra-fluoroethylene, which provides an internal reinforcement to create thin, durable sheeting and to increase flexibility and breathability. Silicone sheets have variable adhesion properties, with some being self-adhesive whilst others require taping to fix them to the skin. Silicone sheets are not suitable for use on large areas of skin and on mobile body parts such as the joints. Patients may be reluctant to use the sheets on visible areas such as the face and compliance with this treatment is often an issue [10]. Silicone gel is applied to the skin as a thin layer where it dries to form an adherent, transparent, flexible silicone sheet that is impermeable to fluids. Such gels are suitable for use on visible areas such as the face and hands, and their ease of application (twice a day) is associated with increased patient preference and compliance [12].

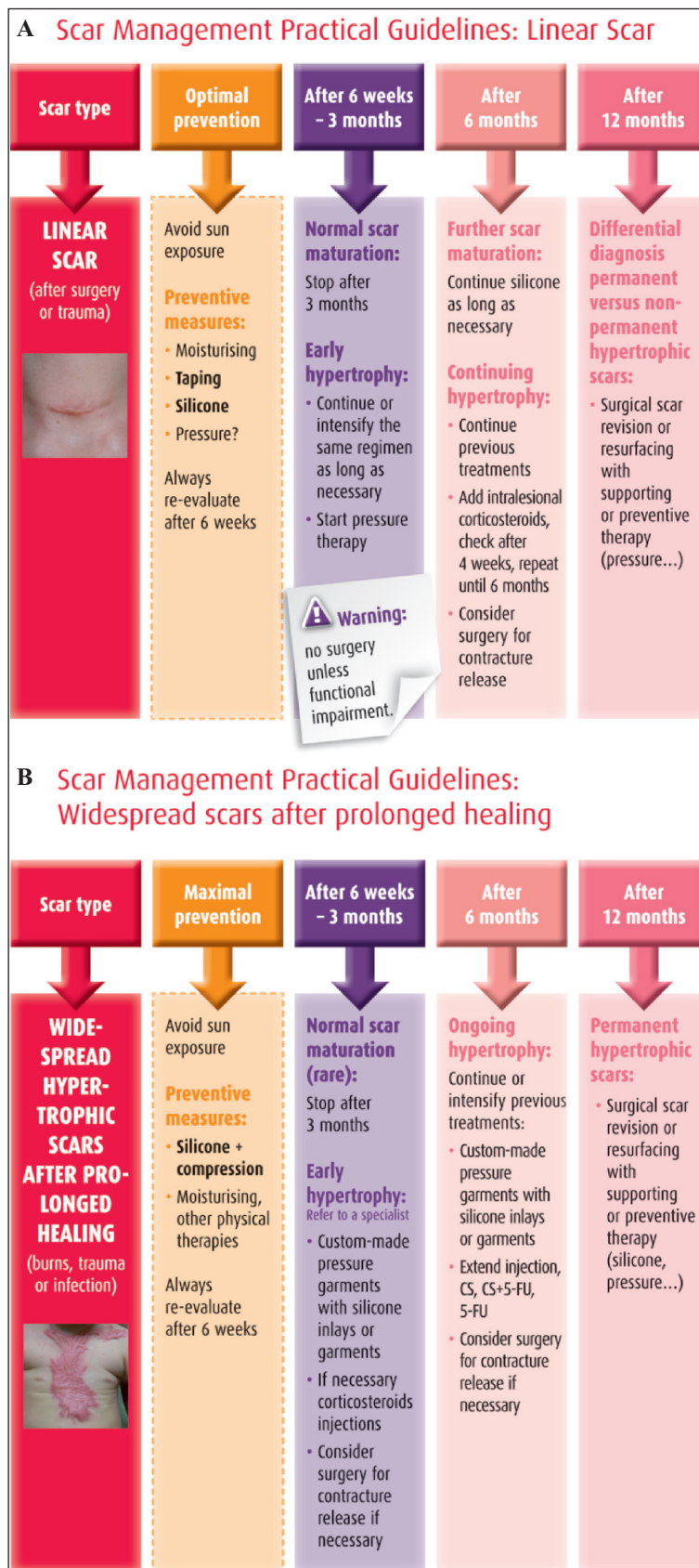


Figure 1. Practical guidelines for the management of hypertrophic and keloid scars [5].

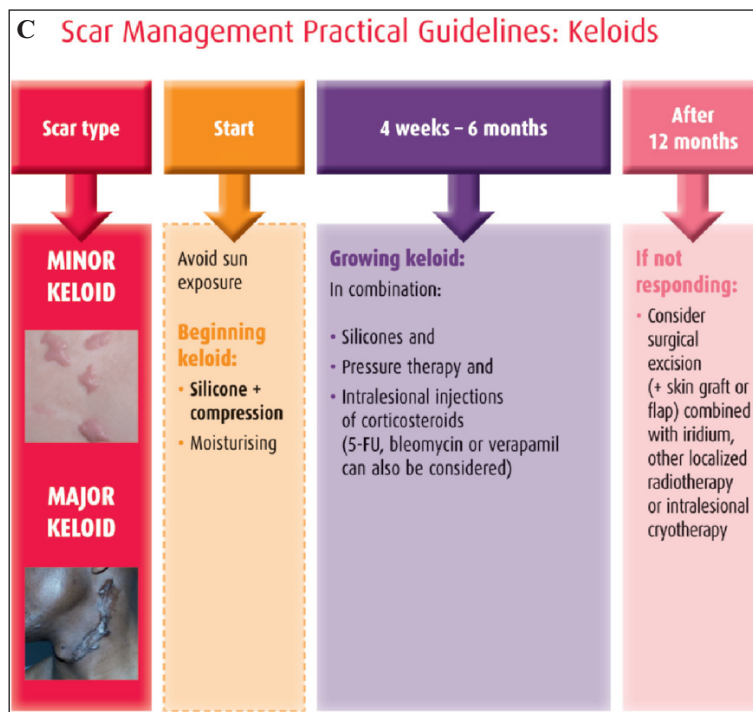


Figure 1. (Continued)

Mechanism of action

Many explanations for the mechanism of action of silicone products have been proposed. For example, silicones may raise the surface temperature of the skin, which can increase collagenase activity leading to collagen breakdown [13]. Furthermore, a negative static electric field between the silicone product and the skin may cause realignment of collagen, resulting in shrinkage of scars [14, 15].

However, occlusion and hydration of the stratum corneum are now universally accepted as the major mechanisms responsible for the action of silicones [10]. Transepidermal water loss is increased following a full thickness wound and may take over one year to return to pre-wound levels [7]. A high loss of water from the epidermis may lead to dehydration of keratinocytes. These cells may then release cytokines to activate dermal fibroblasts to increase collagen production which can lead to excessive scarring [10].

Studies have demonstrated that silicone sheets decrease evaporation of water from the skin and increase hydration of the stratum corneum [16-18]. The reduction in transepidermal water loss will reduce the stimulation of keratinocytes, which in turn will stop producing cytokines and so dermal fibroblasts will not be activated. Occlusion is also an important component of the mechanism of action of silicone products, with a study showing a greater improvement in scars treated with silicone cream containing 20% silicone oil and occlusive dressing compared with those treated with silicone cream covered with gauze [19].

In vitro research has shown that the production of basic fibroblast growth factor (bFGF) can be increased by silicone products [20]. An increase in bFGF levels in fibroblasts leads to a reduction in collagen production. Another investigation indicated that silicone sheeting may act by down-regulating the production of the fibrogenic cytokine, transforming growth factor β 2, by fibroblasts [21].

Re-evaluation of silicone products: latest clinical evidence

Previous and current guidelines recommend silicone products as safe and effective first-line non-invasive options for the prevention and treatment of hypertrophic scars and keloids [5, 6]. The earlier recommendations were based on the results of clinical studies that were published at that time [22-33]. The latest guidelines also take into account the results of many recently published studies, some of which are considered here in more detail.

Several recent studies have confirmed the safety and efficacy of silicone sheeting for scar prevention and treatment [34-36]. For example, Sakuraba *et al.* showed that silicone sheets placed over wounds two weeks after median sternotomy effectively prevented the formation of keloids over 24 weeks in nine patients [34]. Li-Tsang *et al.* conducted a randomised clinical trial which showed that silicone sheeting significantly reduced the thickness and improved the pliability ($p < 0.001$) of severe post-traumatic hypertrophic scars in 45 Chinese patients after six months of treatment with non-significant improvements in pain and itchiness [35]. In addition, a recent meta-analysis of 15 studies involving 615 people showed that silicone sheeting reduced the incidence of hypertrophic scarring in high-risk individuals compared with no treatment (response rate: 0.46; 95% confidence interval 0.21–0.98) [37].

Compliance with silicone sheets can be improved through patient education programmes. A study of 25 patients with hypertrophic burn scars showed that patients who received detailed education on the use of silicone sheets had significantly better compliance with their treatment compared with those who received conventional education ($p < 0.001$) and this translated into significantly improved scar outcomes at six months (e.g., pigmentation ($p = 0.02$), height ($p = 0.03$) and pliability ($p = 0.02$)) [38].

Since the publication of a previous set of scar management guidelines in 2002 [6], several clinical studies of new silicone gels have been published which have shown that these gels have at least equivalent efficacy to silicone sheets for scar management and that patients may find the gel formulations easier to use [12, 39]. Chernoff *et al.* conducted a study in which 30 patients with bilateral scars resulting from laser exfoliation each had one scar treated for 90 days with either silicone gel, silicone gel sheeting or a combination of these products, and the other scar was untreated [12]. The results showed that the silicone gel and combination treatment were associated with improved resolution of scars compared with silicone gel sheeting alone. In addition, the patients rated the silicone gel as being significantly easier to use than the silicone gel sheeting ($p < 0.001$) [12]. In another study, Karagoz *et al.* showed that silicone gel was as effective as silicone sheeting at improving scars as assessed with the Vancouver scar scale in a six-month study of 45 post-burn hypertrophic scars. Both of these silicone products were significantly more effective at improving these scars than Contractubex, a topical onion extract containing heparin and allantoin ($p < 0.05$) [39].

Several other recently conducted studies have confirmed the beneficial effects of silicone gels in the prevention and treatment of scars. Chan *et al.* conducted a randomised, placebo-controlled, double-blind clinical trial which showed that silicone gel was effective in preventing the development of hypertrophic scars after median sternotomy wounds [40]. The study included 50 Asian patients and their wounds were divided into two halves with one half being treated with silicone gel and the other half being treated with a placebo gel for three months. The silicone gel was associated with a significant reduction in scores for scar pigmentation, vascularity, pliability, height, pain and itchiness ($p \leq 0.02$) [40].

Signorini *et al.* showed that the application of silicone gels to recent post-surgical scars was associated with significant improvements in clinical outcomes compared with placebo (e.g., scar quality, $p < 0.001$ between the treatment groups) [41]. A total of 160 patients were included in this study and only 7% of the silicone gel-treated patients had hypertrophic scars or keloids after four months of treatment, compared with 26% of the placebo-treated patients. All of the patients considered the gel was easy to apply and none reported any side effects [41]. In a randomised, double-blind, placebo-controlled study of silicone gel in 23 patients with burn scars, van der Wal *et al.* showed that the silicone gel significantly improved the roughness of the scars ($p = 0.012$) and that patients experienced significantly less itching ($p = 0.013$) during six months of treatment [42]. Another small non-comparative study indicated that silicone gel is effective in reducing scar pigmentation and elevation. In this study of six patients with mature scars, eight weeks of treatment with silicone gel was also associated with a 7.2% decrease in scar collagen and a 3% increase in blood flow in the scar [43].

Compression therapy

A growing body of evidence supports the use of compression therapy as a scar management measure. The current

guidelines recommend compression therapy for the treatment of hypertrophic scars and keloids, in particular after burn injuries. Pressure garments should also be considered as a prophylactic measure in wounds that take more than 14 days to heal spontaneously [5]. Pressure therapy should only be applied once the wound has closed and the patient is able to tolerate the pressure. Additional benefits of pressure therapy include relief of oedema, itchiness and pain [5]. Disadvantages of pressure therapy are the cost of treatment, since pressure garments are usually custom made, and poor patient compliance, since the garments are often uncomfortable and have to be worn for most of the day [44].

Several, but not all, recently published clinical studies on the use of pressure garments for scar treatment have reported beneficial effects. Engrav *et al.* showed that pressure therapy improved clinical outcomes in 54 patients with moderate to severe scarring. Patients with forearm injuries received normal and low compression on their wounds. The results showed that normal *versus* low compression resulted in wounds which were significantly softer (difference: -1.7 durometer units; 95% confidence interval -2.8 – -0.6), thinner (difference: -0.65 mm (95% confidence interval -1.2 – -0.13) and had improved clinical appearance [45]. A study conducted by Van den Kerchove *et al.* showed that garments which deliver a mean pressure of 15 mmHg were associated with significant improvements in scar thickness ($p = 0.027$) but not erythema ($p = 0.64$) compared with garments that delivered lower pressures in 60 patients with 76 burn scars [46]. A recent meta-analysis of six studies of pressure garments involving 316 patients also found that this therapy is associated with a significant reduction in scar height (standardised mean difference -0.31; 95% confidence interval -0.63 – 0.0), but did not find any other benefits in terms of composite assessment scores and measures of scar vascularity and colour [47]. Furthermore, a prospective randomised study of 122 patients with burns found that pressure therapy *versus* no therapy did not affect the median time to wound maturation (266 vs 273 days, respectively; $p = 0.51$) or decrease the mean length of hospital stay (27 vs 25 days, respectively; $p > 0.05$) [48].

Compression therapy may be used as part of combination therapy with silicones. A study conducted by Li-Tsang *et al.* showed that this combination therapy was associated with a significant reduction in scar thickness compared with a control group (massage therapy) after only two months of treatment ($p < 0.001$) [49]. In contrast, the silicone monotherapy was shown to reduce scar pain and pruritus, but not scar thickness. This study included 104 patients with hypertrophic scars, mainly due to burning and scalding injuries [49].

Medical ointments and creams

Several medical ointments and creams, such as menthol creams, topical anti-histamines (e.g., doxepin) and topical calcineurin inhibitors, may be useful in the treatment of scar pruritus, despite a lack of supporting evidence from published clinical studies [5, 50]. In addition, some, but not all studies have shown that topically applied imiquimod 5% may reduce the recurrence rate of keloids following surgical excision [51-53].

Physical treatments

Physical treatments for scars include massage therapy and physiotherapy (e.g., splinting and taping) [5]. These treatments should be combined with silicone and pressure therapy when possible.

Although massage is anecdotally reported to be beneficial for the treatment of scars, there is only very weak clinical evidence currently available to support its use [54]. Available data suggests that massage therapy may reduce pruritus and pain, and may improve the range of motion and appearance of the scar [54]. In addition, the creams that are used as part of massage therapy may beneficially hydrate the skin. The latest guidelines recommend that the type of massage therapy should be adapted to the stage of scar maturation [5].

Splinting may be applied to scars at an early stage of maturation in body areas that are prone to developing contractures (e.g., neck, elbow, axilla) and may also be combined with silicone therapy to improve outcomes [5, 55]. Taping may reduce hypertrophic scar formation by decreasing tension at the wound's edges [56].

Invasive management options

Several invasive scar treatments may be used in dermatological practice, including intralesional injections of corticosteroids with or without 5-fluorouracil, cryotherapy, radiotherapy, laser therapy and botulinum toxin A.

Corticosteroid injections

Corticosteroid injections (e.g., triamcinolone acetonide) can be used to treat hypertrophic scars and keloids as monotherapy or in combination with other therapies. The response rate to this treatment is between 50 and 100%, and the recurrence rate is between nine and 50% [2, 57]. Local side effects include skin and subcutaneous tissue atrophy, capillary dilatation and hypopigmentation [2].

Other intralesional injections

5-Fluorouracil may be injected intralesionally, alone or with corticosteroids, to treat widespread hypertrophic scars and keloids [5, 58]. A retrospective review of medical charts of patients with keloids (n = 102) showed that those who were treated with 5-fluorouracil together with steroids after surgical excision had a numerically greater reduction in lesion size compared with those who were treated with corticosteroids only after excision (92% vs 73%, respectively) [59]. Another study by Wu *et al.* demonstrated that surgical removal of earlobe keloids followed by intralesional injection of 5-fluorouracil and corticosteroid prevented relapse in all 83 (100%) patients over a mean of seven months of follow-up [60]. The main side effects associated with 5-fluorouracil injections include pain, purpura formation and a burning sensation.

Other agents that may be injected into keloid scars include bleomycin and verapamil, although the clinical evidence to support these options is currently more limited. Bleomycin was shown to effectively flatten the majority of scars in a study of 50 patients with keloids or hypertrophic scars

and was associated with a low recurrence rate of 14% [61]. In another study, bleomycin was shown to be particularly effective for the treatment of keloids and hypertrophic scars larger than 100 mm² in size [62]. Verapamil has also been shown to effectively treat keloids either as monotherapy, or as adjuvant therapy after surgical excision with or without silicone therapy [63-65].

Cryotherapy

Cryotherapy may be used to treat recalcitrant keloids. In this procedure, a metal rod is introduced into the keloid which is then destroyed by extreme cooling [5, 66, 67]. A study by Har-Shai *et al.* showed that intralesional cryotherapy is associated with a significant 67% reduction in the volume of recalcitrant keloid scars (p<0.005) as well as decreases in scar hardness, elevation and erythema [66]. The main side effect associated with this treatment is hypopigmentation [67].

Radiotherapy

Adjuvant radiotherapy (e.g., brachytherapy with Iridium 192 or electron-beam irradiation) is advocated following surgical excision of keloids to reduce their rate of recurrence [5]. For example, post-excisional brachytherapy has been associated with a low keloid recurrence rate of 5-24% [68-70]. Disadvantages of this treatment are radiodermatitis, atrophy and the theoretical possibility of carcinogenesis.

Laser and light therapies

Scar prevention

Since 1983, clinical, histological and immunohistochemical studies have demonstrated that lasers have "photo-biomodulation" capabilities, inducing tissue regeneration which is similar to the scarless wound healing that occurs in foetal tissue [71]. The pulsed dye laser, applied on the day of suture removal, with low fluences (about 4.5 J/cm²) and short pulse duration (about 1.5 to 2 ms) remains the gold standard. This treatment has a transient purpuric effect. Depending on patient risk factors and history, sessions can be repeated every three to four weeks. Recently, some new laser therapies have been shown to provide good to excellent results in some clinical series, including diode laser EKKYO just after wound closure and non-ablative or ablative fractional lasers just before wound closure or on the day of suture removal [72]. Sessions can be repeated depending on the patient's risk of developing a scar and on the evolution of the scar itself. As is usual with laser therapy, indications, settings, post-operative care and follow-up must be adapted to the patient's phototype to minimise complications such as scarring or depigmentation.

Scar management

Except for ablative CO₂ or Er:YAG lasers which are used to remove major scars, lasers are most often used as a non-invasive option to improve scar texture, telangiectasia or hyperpigmentation, or to prevent scar recurrence after a surgical revision. Lasers must always be used in combination with occlusion/compression therapy and are often immediately followed by intralesional or laser-assisted delivery of corticosteroids. In a recent meta-analysis, pulsed-dye lasers

(low fluence, short pulse duration) were shown to be the only laser treatment to have evidence-based efficacy for the treatment of scars [73]. In daily clinical practice, other “vascular” lasers (e.g., KTP 532 nm; Nd-YAG LP 1064 nm) and intense pulsed lights are used with success. Non-ablative or ablative fractional lasers are increasingly being used for the treatment of scars, with a growing body of supporting evidence from case reports and series, especially for post-burn scars for which they provide good to excellent improvements of texture, thickness, contracture, pruritus, pain and dyspigmentation [74]. The exact mechanism of action of lasers is not yet clearly understood. However, they seem to be able to induce a remodelling effect and also to induce differentiation and migration of “niched” pilo-sebaceous melanoblasts.

In 2014, there is still uncertainty about which laser therapy is optimal for each type of scar and further studies are needed to address this. However, laser therapy remains one of the key treatment options for scar management around the world.

Botulinum toxin A

The potential of botulinum toxin A to decrease tensile forces on post-surgical or post-traumatic scars (especially on the face and neck) and to minimise these scars is well-known, and this treatment has been used by surgeons for about 10 years [75]. More recently, *in vitro* and animal studies have reported that botulinum toxin may act on the biological behaviour of fibroblasts, although its mechanism of action is still debated [76, 77]. Currently only a few reports have discussed the doses of botulinum toxin that are required for scar prevention. Consequently we recommend that botulinum toxin is given four to seven days before surgery perpendicular to the anticipated wound to reduce tensile forces with doses adjusted according to the muscles involved and to avoid muscular imbalance. In hypertrophic scars or minor keloids, a dose of 2.5 Speywood Units/cm² (or 1 Allergan Unit or DL 50/cm²) should be used.

Conclusions

There is a growing number of options for the prevention and treatment of hypertrophic scars and keloids, although as yet the published clinical evidence to support many of these is rather limited. The scar management guidelines that are presented in this article are based on the evidence available to date. Silicone sheets and gels are recommended as the current gold standard, first-line non-invasive option for the prevention and treatment of hypertrophic scars and keloids on the basis of the results of over 20 recent clinical studies. These studies have confirmed the efficacy and safety of silicone products for scar prevention and treatment. Additional scar management measures with a reasonable level of supporting evidence include compression therapy and intralesional corticosteroids. Further study of other preventative and treatment options is warranted to strengthen the evidence base on which guideline recommendations can be based. ■

Disclosure. *Acknowledgements:* We thank the following co-ordinating editors and authors of the *Scar Management Practical Guidelines* book for their invaluable contributions to the development of these guidelines: Esther Middelkoop (Association of Dutch Burn Centres, Beverwijk and Department of Plastic Reconstructive and Hand Surgery, Research Institute MOVE, VU University Medical Centre, Amsterdam, the Netherlands); Stan Monstrey (Plastic and Reconstructive Surgery Department, Burn Centre, Ghent University Hospital, Ghent, Belgium); Luc Téot (Wound Healing Unit & Burns Surgery, Montpellier University Hospital, Montpellier, France); Jan-Jeroen Vranckx (Plastic and Reconstructive Surgery Department, KUL Leuven University Hospitals, Leuven, Belgium); Franco Bassetto (Plastic Surgery Institute, University of Padova, Italy); Nele Brusselaers (Burn Centre and Department of General Internal Medicine, Infectious Diseases and Psychosomatic Medicine, Ghent University Hospital, Ghent, Belgium); Maarten Doornaert and Henk Hoeksema (Department of Plastic and Reconstructive Surgery, Ghent University Hospital, Ghent, Belgium); Anibal Justiniano (Institute of Health Sciences, Catholic University, Porto, Portugal); Benoît Lengelé (Anatomy Department, Catholic University of Louvain, Brussels, Belgium); Ali Pirayesh (Amsterdam Plastic Surgery, Amsterdam, the Netherlands and Department of Plastic and Reconstructive Surgery, Ghent University Hospital, Ghent, Belgium); Fabrice Rogge (Plastic and Reconstructive Surgery, Bruges, Belgium); Claude Roques (CSRE Lamalou le Haut, Pediatric Rehabilitation Centre, Lamalou-Les-Bains, France); Xavier Santos Heredero (Plastic and Reconstructive Surgery Department, University Hospitals of Madrid Monteprincipe y Torrelodones, Madrid, Spain); Eric Van den Kerckhove (Physical Medicine and Rehabilitation, University Hospital Gasthuisberg, KUL Leuven University Hospitals, Leuven, Belgium); Helga Van De Velde (Institute Helga Van De Velde, Ghent, Belgium); Nancy Van Loey (Association of Dutch Burns Centres, Beverwijk, the Netherlands); Antoine J van Trier (Department of Plastic, Reconstructive and Handsurgery, Red Cross Hospital, Beverwijk, the Netherlands); Ulrich E. Ziegler (Plastic and Aesthetic Surgery, Stuttgart Sporerstrasse, Germany). *Financial support:* Editorial assistance in the preparation of this manuscript was provided by David Harrison, Medscript Communications, funded by Meda Pharma SA. *Conflict of interest:* none.

References

1. Bayat A, McGrouther DA, Ferguson MW. Skin scarring. *BMJ* 2003; 326: 88-92.
2. Juckett G, Hartman-Adams H. Management of keloids and hypertrophic scars. *Am Fam Physician* 2009; 80: 253-60.
3. van der Veer WM, Bloemen MC, Ulrich MM, et al. Potential cellular and molecular causes of hypertrophic scar formation. *Burns* 2009; 35: 15-29.

4. Ashcroft GS, Horan MA, Ferguson MW. Aging alters the inflammatory and endothelial cell adhesion molecule profiles during human cutaneous wound healing. *Lab Invest* 1998;78: 47-58.
5. Middelkoop E, Monstrey S, Teot L, Vranckx JJ, editors. *Scar management practical guidelines*. Published by Maca-Cloetens, 2011, 1-109.
6. Mustoe TA, Cooter RD, Gold MH, et al. International clinical recommendations on scar management. *Plast Reconstr Surg* 2002; 110: 560-71.
7. Suetake T, Sasai S, Zhen YX, Ohi T, Tagami H. Functional analyses of the stratum corneum in scars. Sequential studies after injury and comparison among keloids, hypertrophic scars, and atrophic scars. *Arch Dermatol* 1996; 132: 1453-8.
8. Tandara AA, Kloeters O, Mogford JE, Mustoe TA. Hydrated keratinocytes reduce collagen synthesis by fibroblasts via paracrine mechanisms. *Wound Repair Regen* 2007; 15: 497-504.
9. O'Shaughnessy KD, De La Garza M, Roy NK, Mustoe TA. Homeostasis of the epidermal barrier layer: a theory of how occlusion reduces hypertrophic scarring. *Wound Repair Regen* 2009; 17: 700-8.
10. Mustoe TA. Evolution of silicone therapy and mechanism of action in scar management. *Aesthetic Plast Surg* 2008; 32: 82-92.
11. Berman B, Perez OA, Konda S, et al. A review of the biologic effects, clinical efficacy, and safety of silicone elastomer sheeting for hypertrophic and keloid scar treatment and management. *Dermatol Surg* 2007; 33: 1291-302.
12. Chernoff WG, Cramer H, Su-Huang S. The efficacy of topical silicone gel elastomers in the treatment of hypertrophic scars, keloid scars, and post-laser exfoliation erythema. *Aesthetic Plast Surg* 2007; 31: 495-500.
13. Musgrave MA, Umraw N, Fish JS, Gomez M, Cartotto RC. The effect of silicone gel sheets on perfusion of hypertrophic burn scars. *J Burn Care Rehabil* 2002; 23: 208-14.
14. Har-Shai Y, Lindenbaum E, Tendler M, Gamliel-Lazarovich A, Feitelberg L, Hirshowitz B. Negatively charged static electricity stimulation as a possible mechanism for enhancing the involution of hypertrophic and keloid scars. *Isr Med Assoc J* 1999; 1: 203-5.
15. Hirshowitz B, Lindenbaum E, Har-Shai Y, Feitelberg L, Tendler M, Katz D. Static-electric field induction by a silicone cushion for the treatment of hypertrophic and keloid scars. *Plast Reconstr Surg* 1998; 101: 1173-83.
16. Quinn KJ, Evans JH, Courtney JM, Gaylor JD, Reid WH. Non-pressure treatment of hypertrophic scars. *Burns Incl Therm Inj* 1985; 12: 102-8.
17. Gilman TH. Silicone sheet for treatment and prevention of hypertrophic scar: a new proposal for the mechanism of efficacy. *Wound Repair Regen* 2003; 11: 235-6.
18. Branagan M, Chenery DH, Nicholson S. Use of infrared attenuated total reflectance spectroscopy for the in vivo measurement of hydration level and silicone distribution in the stratum corneum following skin coverage by polymeric dressings. *Skin Pharmacol Appl Skin Physiol* 2000; 13: 157-64.
19. Sawada Y, Sone K. Treatment of scars and keloids with a cream containing silicone oil. *Br J Plast Surg* 1990; 43: 683-8.
20. Hanasono MM, Lum J, Carroll LA, Mikulec AA, Koch RJ. The effect of silicone gel on basic fibroblast growth factor levels in fibroblast cell culture. *Arch Facial Plast Surg* 2004; 6: 88-93.
21. Kuhn MA, Moffit MR, Smith PD, et al. Silicone sheeting decreases fibroblast activity and downregulates TGFbeta2 in hypertrophic scar model. *Int J Surg Investig* 2001; 2: 467-74.
22. Gold MH, Foster TD, Adair MA, Burlison K, Lewis T. Prevention of hypertrophic scars and keloids by the prophylactic use of topical silicone gel sheets following a surgical procedure in an office setting. *Dermatol Surg* 2001; 27: 641-4.
23. Cruz-Korchin NI. Effectiveness of silicone sheets in the prevention of hypertrophic breast scars. *Ann Plast Surg* 1996; 37: 345-8.
24. Ahn ST, Monafu WW, Mustoe TA. Topical silicone gel for the prevention and treatment of hypertrophic scar. *Arch Surg* 1991; 126: 499-504.
25. Fulton JE Jr. Silicone gel sheeting for the prevention and management of evolving hypertrophic and keloid scars. *Dermatol Surg* 1995; 21: 947-51.
26. Carney SA, Cason CG, Gowar JP, et al. Cica-Care gel sheeting in the management of hypertrophic scarring. *Burns* 1994; 20: 163-7.
27. Lee SM, Ngim CK, Chan YY, Ho MJ. A comparison of Sil-K and Epiderm in scar management. *Burns* 1996; 22: 483-7.
28. Sproat JE, Dalcin A, Weitauer N, Roberts RS. Hypertrophic sternal scars: silicone gel sheet versus Kenalog injection treatment. *Plast Reconstr Surg* 1992; 90: 988-92.
29. Katz BE. Silicone gel sheeting in scar therapy. *Cutis* 1995; 56: 65-7.
30. Berman B, Flores F. Comparison of a silicone gel-filled cushion and silicon gel sheeting for the treatment of hypertrophic or keloid scars. *Dermatol Surg* 1999; 25: 484-6.
31. Gold MH. A controlled clinical trial of topical silicone gel sheeting in the treatment of hypertrophic scars and keloids. *J Am Acad Dermatol* 1994; 30: 506-7.
32. Agarwal US, Jain D, Gulati R, Bhargava P, Mathur NK. Silicone gel sheet dressings for prevention of post-minigraft cobblestoning in vitiligo. *Dermatol Surg* 1999; 25: 102-4.
33. Ahn ST, Monafu WW, Mustoe TA. Topical silicone gel: a new treatment for hypertrophic scars. *Surgery* 1989; 106: 781-6.
34. Sakuraba M, Takahashi N, Akahoshi T, Miyasaka Y, Suzuki K. Use of silicone gel sheets for prevention of keloid scars after median sternotomy. *Surg Today* 2011; 41: 496-9.
35. Li-Tsang CW, Lau JC, Choi J, Chan CC, Jianan L. A prospective randomized clinical trial to investigate the effect of silicone gel sheeting (Cica-Care) on post-traumatic hypertrophic scar among the Chinese population. *Burns* 2006; 32: 678-83.
36. Majan JI. Evaluation of a self-adherent soft silicone dressing for the treatment of hypertrophic postoperative scars. *J Wound Care* 2006; 15: 193-6.
37. O'Brien L, Pandit A. Silicon gel sheeting for preventing and treating hypertrophic and keloid scars. *Cochrane Database Syst Rev* 2006: CD003826.
38. So K, Umraw N, Scott J, Campbell K, Musgrave M, Cartotto R. Effects of enhanced patient education on compliance with silicone gel sheeting and burn scar outcome: a randomized prospective study. *J Burn Care Rehabil* 2003; 24: 411-7.
39. Karagoz H, Yuksel F, Ulkur E, Evinc R. Comparison of efficacy of silicone gel, silicone gel sheeting, and topical onion extract including heparin and allantoin for the treatment of postburn hypertrophic scars. *Burns* 2009; 35: 1097-103.
40. Chan KY, Lau CL, Adeeb SM, Somasundaram S, Nasir-Zahari M. A randomized, placebo-controlled, double-blind, prospective clinical trial of silicone gel in prevention of hypertrophic scar development in median sternotomy wound. *Plast Reconstr Surg* 2005; 116: 1013-20.
41. Signorini M, Clementoni MT. Clinical evaluation of a new self-drying silicone gel in the treatment of scars: a preliminary report. *Aesthetic Plast Surg* 2007; 31: 183-7.
42. van der Wal MB, van Zuijlen PP, van de Ven P, Middelkoop E. Topical silicone gel versus placebo in promoting the maturation of burn scars: a randomized controlled trial. *Plast Reconstr Surg* 2010; 126: 524-31.
43. Murison M, James W. Preliminary evaluation of the efficacy of dermatix silicone gel in the reduction of scar elevation and pigmentation. *J Plast Reconstr Aesthet Surg* 2006; 59: 437-9.
44. Ripper S, Renneberg B, Landmann C, Weigel G, Germann G. Adherence to pressure garment therapy in adult burn patients. *Burns* 2009; 35: 657-64.
45. Engrav LH, Heimbach DM, Rivara FP, et al. 12-Year within-wound study of the effectiveness of custom pressure garment therapy. *Burns* 2010; 36: 975-83.
46. Van den Kerckhove E, Stappaerts K, Fieuws S, et al. The assessment of erythema and thickness on burn related scars during pressure garment therapy as a preventive measure for hypertrophic scarring. *Burns* 2005; 31: 696-702.
47. Anzarut A, Olson J, Singh P, Rowe BH, Tredget EE. The effectiveness of pressure garment therapy for the prevention of abnormal scarring after burn injury: a meta-analysis. *J Plast Reconstr Aesthet Surg* 2009; 62: 77-84.
48. Chang P, Laubenthal KN, Lewis RW, Rosenquist MD, Lindley-Smith P, Kealey GP. Prospective, randomized study of the efficacy of pressure garment therapy in patients with burns. *J Burn Care Rehabil* 1995; 16: 473-5.

- 49.** Li-Tsang CW, Zheng YP, Lau JC. A randomized clinical trial to study the effect of silicone gel dressing and pressure therapy on post-traumatic hypertrophic scars. *J Burn Care Res* 2010; 31: 448-57.
- 50.** Goutos I, Dziewulski P, Richardson PM. Pruritus in burns: review article. *J Burn Care Res* 2009; 30: 221-8.
- 51.** Berman B, Kaufman J. Pilot study of the effect of postoperative imiquimod 5% cream on the recurrence rate of excised keloids. *J Am Acad Dermatol* 2002; 47: S209-11.
- 52.** Chuangsuwanich A, Gunjittisomram S. The efficacy of 5% imiquimod cream in the prevention of recurrence of excised keloids. *J Med Assoc Thai* 2007; 90: 1363-7.
- 53.** Cacao FM, Tanaka V, Messina MC. Failure of imiquimod 5% cream to prevent recurrence of surgically excised trunk keloids. *Dermatol Surg* 2009; 35: 629-33.
- 54.** Shin TM, Bordeaux JS. The role of massage in scar management: a literature review. *Dermatol Surg* 2012; 38: 414-23.
- 55.** Richard R, Ward RS. Splinting strategies and controversies. *J Burn Care Rehabil* 2005; 26: 392-6.
- 56.** Atkinson JA, McKenna KT, Barnett AG, McGrath DJ, Rudd M. A randomized, controlled trial to determine the efficacy of paper tape in preventing hypertrophic scar formation in surgical incisions that traverse Langer's skin tension lines. *Plast Reconstr Surg* 2005; 116: 1648-56.
- 57.** Niessen FB, Spauwen PH, Schalkwijk J, Kon M. On the nature of hypertrophic scars and keloids: a review. *Plast Reconstr Surg* 1999; 104: 1435-58.
- 58.** Fitzpatrick RE. Treatment of inflamed hypertrophic scars using intralesional 5-FU. *Dermatol Surg* 1999; 25: 224-32.
- 59.** Davison SP, Dayan JH, Clemens MW, Sonni S, Wang A, Crane A. Efficacy of intralesional 5-fluorouracil and triamcinolone in the treatment of keloids. *Aesthet Surg J* 2009; 29: 40-6.
- 60.** Wu XL, Gao Z, Song N, Liu W. Clinical study of auricular keloid treatment with both surgical excision and intralesional injection of low-dose 5-fluorouracil and corticosteroids. *Zhonghua Yi Xue Za Zhi* 2009; 89: 1102-5.
- 61.** Aggarwal H, Saxena A, Lubana PS, Mathur RK, Jain DK. Treatment of keloids and hypertrophic scars using bleomycin. *J Cosmet Dermatol* 2008; 7: 43-9.
- 62.** Naeini FF, Najafian J, Ahmadvpour K. Bleomycin tattooing as a promising therapeutic modality in large keloids and hypertrophic scars. *Dermatol Surg* 2006; 32: 1023-9.
- 63.** Copcu E, Sivrioglu N, Oztan Y. Combination of surgery and intralesional verapamil injection in the treatment of the keloid. *J Burn Care Rehabil* 2004; 25: 1-7.
- 64.** D'Andrea F, Brongo S, Ferraro G, Baroni A. Prevention and treatment of keloids with intralesional verapamil. *Dermatology* 2002; 204: 60-2.
- 65.** Margaret Shanthi FX, Ernest K, Dhanraj P. Comparison of intralesional verapamil with intralesional triamcinolone in the treatment of hypertrophic scars and keloids. *Indian J Dermatol Venereol Leprol* 2008; 74: 343-8.
- 66.** Har-Shai Y, Sabo E, Rohde E, Hyams M, Assaf C, Zouboulis CC. Intralesional cryosurgery enhances the involution of recalcitrant auricular keloids: a new clinical approach supported by experimental studies. *Wound Repair Regen* 2006; 14: 18-27.
- 67.** Gupta S, Kumar B. Intralesional cryosurgery using lumbar puncture and/or hypodermic needles for large, bulky, recalcitrant keloids. *Int J Dermatol* 2001; 40: 349-53.
- 68.** Arnault JP, Peiffert D, Latache C, Chassagne JF, Barbaud A, Schmutz JL. Keloids treated with postoperative Iridium 192* brachytherapy: a retrospective study. *J Eur Acad Dermatol Venereol* 2009; 23: 807-13.
- 69.** Guix B, Henriquez I, Andres A, Finestres F, Tello JI, Martinez A. Treatment of keloids by high-dose-rate brachytherapy: A seven-year study. *Int J Radiat Oncol Biol Phys* 2001; 50: 167-72.
- 70.** Kuribayashi S, Miyashita T, Ozawa Y, et al. Post-keloidectomy irradiation using high-dose-rate superficial brachytherapy. *J Radiat Res* 2011; 52: 365-8.
- 71.** Leclere FM, Mordon SR. Twenty-five years of active laser prevention of scars: what have we learned? *J Cosmet Laser Ther* 2010; 12: 227-34.
- 72.** Ozog DM, Moy RL. A randomized split-scar study of intraoperative treatment of surgical wound edges to minimize scarring. *Arch Dermatol* 2011; 147: 1108-10.
- 73.** Vrijman C, van Drooge AM, Limpens J, et al. Laser and intense pulsed light therapy for the treatment of hypertrophic scars: a systematic review. *Br J Dermatol* 2011; 165: 934-42.
- 74.** Beachkofsky TM, Henning JS, Hivnor CM. Induction of de novo hair regeneration in scars after fractionated carbon dioxide laser therapy in three patients. *Dermatol Surg* 2011; 37: 1365-8.
- 75.** Sherris DA, Gassner HG. Botulinum toxin to minimize facial scarring. *Facial Plast Surg* 2002; 18: 35-9.
- 76.** Xiao Z, Zhang F, Lin W, Zhang M, Liu Y. Effect of botulinum toxin type A on transforming growth factor beta 1 in fibroblasts derived from hypertrophic scar: a preliminary report. *Aesthetic Plast Surg* 2010; 34: 424-7.
- 77.** Ziade M, Domergue S, Batifol D, et al. Use of botulinum toxin type A to improve treatment of facial wounds: a prospective randomised study. *J Plast Reconstr Aesthet Surg* 2013; 66: 209-14.